

# Acne scarring treatment using skin needling

G. Fabbrocini, N. Fardella, A. Monfrecola, I. Proietti\* and D. Innocenzi\*

Department of Systematic Pathology, Division of Clinical Dermatology, University of Naples Federico II, Naples, Italy; and \*UOC Dermatology Unit, First Faculty of Medicine, Polo Pontino, University of Rome La Sapienza, Rome, Italy

doi:10.1111/j.1365-2230.2009.03291.x

## Summary

**Background.** Acne is a common condition seen in up to 80% of people between 11 and 30 years of age and in up to 5% of older adults. In some patients, it can result in permanent scars that are surprisingly difficult to treat. A relatively new treatment, termed skin needling (needle dermabrasion), seems to be appropriate for the treatment of rolling scars in acne.

**Aim.** To confirm the usefulness of skin needling in acne scarring treatment.

**Methods.** The present study was conducted from September 2007 to March 2008 at the Department of Systemic Pathology, University of Naples Federico II and the UOC Dermatology Unit, University of Rome La Sapienza. In total, 32 patients (20 female, 12 male patients; age range 17–45) with acne rolling scars were enrolled. Each patient was treated with a specific tool in two sessions. Using digital cameras, photos of all patients were taken to evaluate scar depth and, in five patients, silicone rubber was used to make a microrelief impression of the scars. The photographic data were analysed by using the sign test statistic ( $\alpha < 0.05$ ) and the data from the cutaneous casts were analysed by fast Fourier transformation (FFT).

**Results.** Analysis of the patient photographs, supported by the sign test and of the degree of irregularity of the surface microrelief, supported by FFT, showed that, after only two sessions, the severity grade of rolling scars in all patients was greatly reduced and there was an overall aesthetic improvement. No patient showed any visible signs of the procedure or hyperpigmentation.

**Conclusion.** The present study confirms that skin needling has an immediate effect in improving acne rolling scars and has advantages over other procedures.

## Introduction

Acne is a common condition seen in up to 80% of people between 11 and 30 years of age and in up to 5% of older adults. In some patients, the severe inflammatory response results in permanent scars. Scars can involve textural change in the superficial and deep dermis. They

may also be associated with erythema and less often, may show pigmentary changes.

Numerous descriptive terms and surgical techniques have been used to diagnose the types of acne and to improve the appearance of scarring in people with the condition. The use of a simple and universally applicable acne-scar classification system<sup>1</sup> was recently proposed. Goodman and Barron recommend a classification scheme based on the severity of acne scars (Table 1). Once the scar type has been defined, appropriate and effective treatment protocols can be developed. The currently available treatments for acne scarring include laser resurfacing, punch excision, punch elevation, subcutaneous incision chemical peels, microdermoabrasion, dermal grafting, dermal fillers, fat

*Correspondence:* Dr Gabriella Fabbrocini, University of Naples Federico II, Department of Systematic Pathology, Division of Clinical Dermatology, via Pansini 5, 80131 Naples, Italy.  
E-mail: gafabbro@unina.it

Conflict of interest: none declared.

Accepted for publication 8 October 2008

**Table 1** Goodman and Barron classification of acne scar severity.

Grade	Description
1	Macular scarring or flat scarring that is characterized by flat areas of increased or decreased pigmentation visible from a distance of > 500 mm
2	Mild disease that is visible at distances of < 500 mm and can be covered by make-up. Examples include mild rolling acne scars
3	Moderate disease that is visible at $\geq$ 500 mm and is not easily covered with make-up or the normal shadow of a shaved beard. Stretching the skin can flatten the scar. Examples include more significant rolling scars, shallow boxcar scars and mild to moderate hypertrophic scars
4	Severe disease as in grade 3 but scarring is not flattened by stretching the skin. Examples include severe boxcar scars, deep divots, ice pick scars and hypertrophic keloid scarring (very raised/pigmented scars)

transfer, implantation of autologous collagen and cultured and expanded autologous fibroblasts, focal treatment with trichloroacetic acid, and skin needling (needle dermabrasion).

Skin needling has been used since 1995 to achieve percutaneous collagen induction (PCI).<sup>2</sup> It is an effective method for treating acne scars (grades 2–3) and other dermatological lesions. The technique involves puncturing the skin multiple times with a small needle to induce collagen growth. In 1995 Orentreich and Orentreich<sup>2</sup> described 'subcision' as a way of building up connective tissue beneath retracted scars and wrinkles. Desmond Fernandes,<sup>3</sup> simultaneously and independently, used a similar technique to treat the upper lip by inserting a 15-gauge needle into the skin and then tunnelling under the wrinkles in various directions, parallel to the skin surface. Camirand and Doucet treated scars with a tattoo gun to 'needle abrade' them.<sup>4</sup> Although this technique could be used on extensive areas, it was laboriously slow, and the holes in the epidermis were too close and too shallow. All these techniques worked because the needles break old collagen strands in the most superficial layer of the dermis that tether scars or wrinkles. It is presumed that this process promotes removal of damaged collagen growth and induces more collagen immediately under the epidermis.

In order to confirm the usefulness of CIT (collagen induction therapy) in acne scarring treatment, we used this procedure to treat a group of patients affected with acne rolling scars.

## Methods

This study was conducted from September 2007 to March 2008, in accordance with the Helsinki Declaration of 1975. Written and signed informed consent was obtained from all participants.

## Patients

The study was carried out at the Department of Systematic Pathology, University of Naples Federico II and the UOC Dermatology Unit, University of Rome La Sapienza. In total, 32 patients were enrolled in the study (20 female and 12 male patients; age range 17–45 years). Exclusion criteria were: history of an extremely rare but severe form of keloid scarring, diabetes, neuromuscular disease, bleeding disorder, collagen vascular disease, acute or chronic corticosteroid or anticoagulant treatment, presence of skin cancers, warts, solar keratoses or any skin infection and pregnancy. All participants completed the study.

## Assessment and pre-treatment

Before the treatment, the severity of lesions in each patient was scored on a 10-point scale (0 = no lesions; 10 = maximum severity) by an experienced dermatologist involved in the study. Using the Goldman and Barron classification, 3 groups of patients were identified: group A comprised 9 patients with a severity score of > 7 (grade 3; severe rolling scars); group B comprised 19 patients with a severity score of 5–7 (grade 2; moderate rolling scars); and group C had 4 patients with a severity score of < 5 (grade 2; mild rolling scars) (Table 2). Each group of patients was treated with the needling tool (Dermaroller, model MS4; Horst Liebl CEO, Fresenheim, France), which comprised a rolling barrel 10 mm wide, equipped with 96 needles (length 1.5 mm, diameter 0.25 mm) in 4 rows. Depending on the applied pressure, the needles penetrated the scar tissue to a depth of 0.1–1.3 mm.

As percutaneous CIT works best when combined with a scientific skin-care programme to restore a youthful appearance, the skin of each patient was treated with a topical product (Acnomega 100; Merck, Geneva, Switzerland) containing alpha and omega hydroxy acids, omega hydroxy acids, enoxolone and zinc for at least 3 weeks (preparation phase) before the skin needling began.

**Table 2** Scores and grading of patients before and after CIT.

Group A				Group B				Group C			
Score before CIT	Score after CIT	Grading before CIT	Grading after CIT	Score before CIT	Score after CIT	Grading before CIT	Grading after CIT	Score before CIT	Score after CIT	Grading before CIT	Grading after CIT
8	8	3	3	5	3	2	1	4	3	2	1
10	4	3	2	5	5	2	2	3	3	2	2
7	7	3	3	5	3	2	1	2	1	2	1
8	8	3	3	6	6	2	2	4	4	2	2
9	4	3	2	6	3	2	1	–	–	–	–
10	5	3	2	6	3	2	1	–	–	–	–
8	4	3	2	7	7	2	2	–	–	–	–
7	7	3	3	5	5	2	2	–	–	–	–
7	7	3	3	6	6	2	2	–	–	–	–
–	–	–	–	7	3	2	1	–	–	–	–
–	–	–	–	5	5	2	2	–	–	–	–
–	–	–	–	6	6	2	2	–	–	–	–
–	–	–	–	7	3	2	1	–	–	–	–
–	–	–	–	5	5	2	2	–	–	–	–
–	–	–	–	5	3	2	1	–	–	–	–
–	–	–	–	6	6	2	2	–	–	–	–
–	–	–	–	7	7	2	2	–	–	–	–
–	–	–	–	5	5	2	1	–	–	–	–
–	–	–	–	6	3	2	1	–	–	–	–

Before the first treatment began but after the patients had been using the cream,  $\geq 3$  photographs (baseline) were taken of each patient (Fig. 1a) by another dermatologist not involved in the study and filed in a database. In addition, to achieve reliable evidence, for 5 of 32 patients we made a cutaneous cast using silicone rubber to make a microrelief impression. Computerized digital image processing of such specimens provides an objective measurement of the skin's topography, and it has a significant degree of correlation with clinical grading.

During the first session, each patient was prepared in a similar manner to a surgical procedure; the facial skin was disinfected, then a topical anaesthetic (EMLA) was applied, which was left for 60 min.

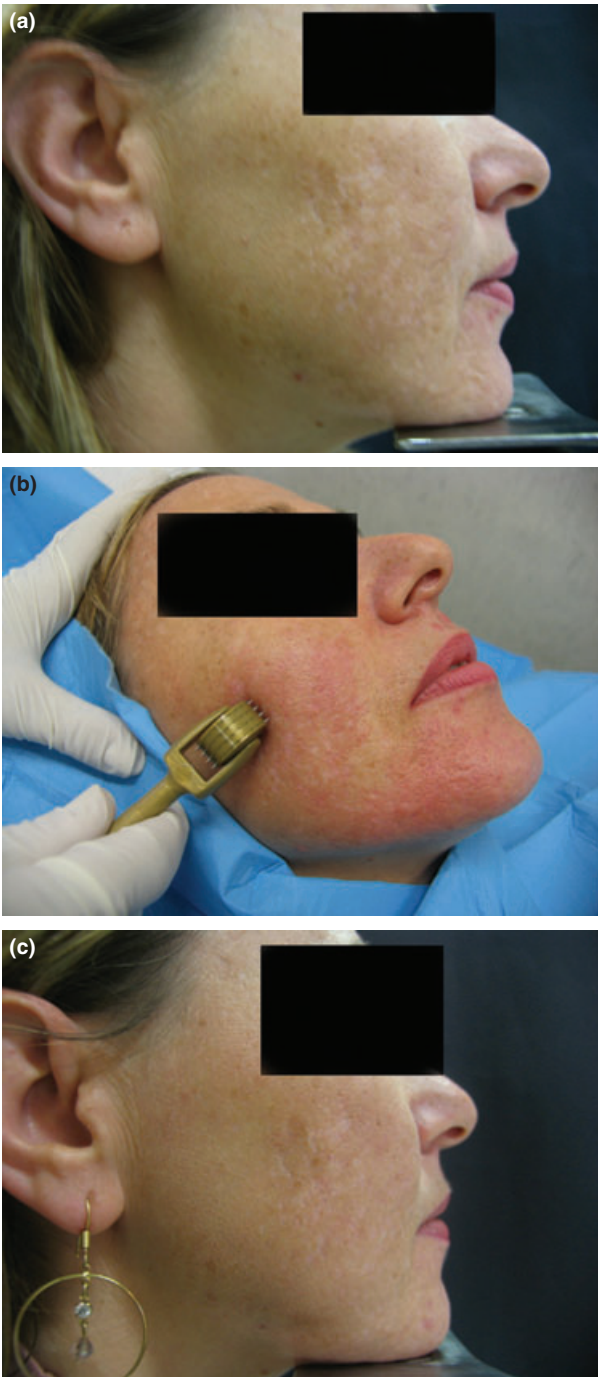
#### Skin needling procedure

The treatment was then carried out by rolling the needling tool over the areas affected by acne scars, four times in four different directions: horizontally, vertically, and diagonally right and left. This ensured an even pricking pattern, resulting in about 250–300 pricks/cm<sup>2</sup>. The microneedles penetrate through the epidermis but do not remove it; the epidermis is only punctured and heals rapidly. The needles seem to separate the cells from each other rather than cut through them, and thus many cells are spared. Because

the needles are set in a roller, every needle initially penetrates at an angle and then goes deeper as the roller turns. Finally the needle is extracted at a converse angle, therefore curving the tracts and reflecting the path of the needle as it rolls into and then out of the skin for about 1.5–2 mm into the dermis. The epidermis, and particularly the stratum corneum, remains intact except for the minute holes, which are about four cells in diameter.

As expected, after the treatment, the skin bled for a short time (Fig. 1b). When bleeding stopped, a serous ooze formed and was removed from the surface of the skin with using sterile saline solution. Further wound treatment was not necessary.

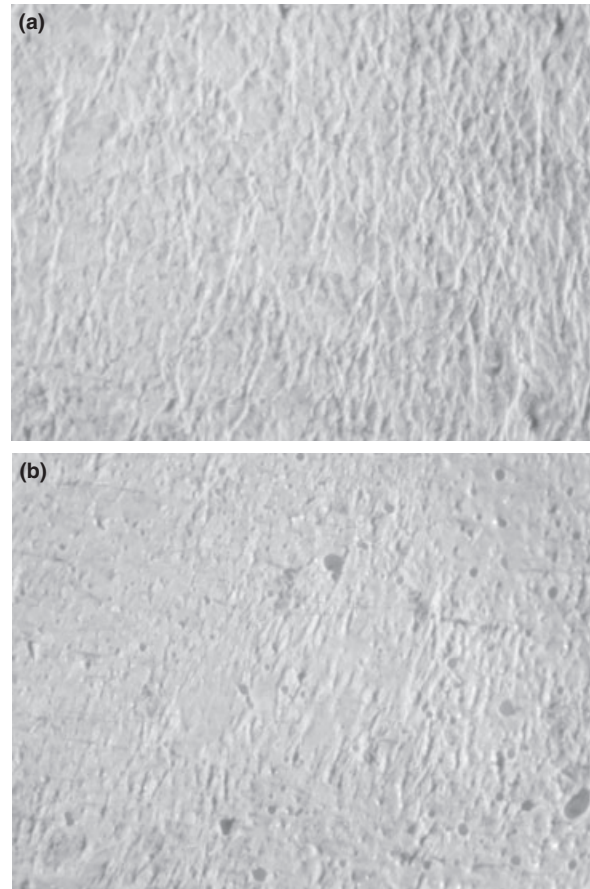
Each patient was seen at a follow-up visit a week later to determine the response to CIT and any side-effects that might have occurred. The second session of treatment was conducted 8 weeks after the first. Before this second intervention, new photographs were taken for each patient by the same dermatologist who had taken the previous ones and filed in the database. At every follow-up, the same experienced dermatologist evaluated the scars, scoring them using the same scale as previously, to assess any clinical improvement in the severity of the lesions. The last follow-up was conducted 8 weeks after the second treatment by the dermatologist who scored the acne scars. At this point, the photographs (Fig. 1c) were compared with the photographs



**Figure 1** (a) Acne rolling scars before the first treatment; (b) after the treatment, the skin bled for a short time; (c) acne rolling scars 16 weeks after the first treatment.

taken before the first treatment and each patient was given a new severity score.

We assessed the real immediate improvement induced by CIT on rolling acne scars after two sessions



**Figure 2** Analysis of degree of irregularity of the microrelief (a) before and (b) after collagen induction therapy.

of skin needling. During the last follow-up, we made another five cutaneous casts that were compared with the ones made before beginning the first treatment and assessed the degree of irregularity in these casts (Fig. 2).

### Statistical analysis

The digital photographic data were analysed using a test for nonparametric data (sign test for paired data). The null ( $H_0$ ) is that the median of the difference is zero ( $P_+ = P_-$ ) and the alternative hypothesis ( $H_A$ ) is that the median of the differences is negative ( $P_+ < P_-$ ),  $\alpha = 0.05$ . The result is given by computing the binomial probability. For the analysis of irregularity of the surface microreliefs, fast Fourier transformation (FFT), with average values of grey obtained along the  $x$  and  $y$  axes. The calculated indexes [irregular skin index (ISI);  $\omega x$  axis and  $\omega y$  axis] are the integrals of areas arising from the distribution of pixels along the axes.

## Results

The results achieved after two sessions of treatment, preceded by the preparation phase, were assessed. After each session of treatment, the facial skin appeared reddened and swollen, but patients stated that the redness and swelling disappeared in 2–3 days. No side-effect was reported or found.

Eight weeks after the first session of CIT, all patients had smoother facial skin and a slight reduction in lesion severity. Eight weeks after the second session of CIT, the improvement in the acne rolling scars was evident: the photographic comparison highlighted that, in each group of patients, as skin became thicker, the relative rolling scar depth was significantly reduced (independent of the lesion grading). In fact, the sign test for paired data ( $P < 0.05$ ), highlighted that the median of the differences is negative, showing that the reduction in severity grade of acne scars, before and after CIT, should be considered significant (Fig. 3).

Analysis of the surface microrelief of the cutaneous casts showed a reduction in degree of irregularity of skin texture in all five patients, with an average reduction of 25% in both axes. This means that the grade of severity of the rolling scars in all patients was greatly reduced after only two sessions. In addition, there were no visible signs of the procedure or any hyperpigmentation seen in any patient.

## Discussion

When a needle penetrates into the skin, the injury causes localized damage and minor bleeding by rupturing fine blood vessels. A completely different picture emerges when thousands of fine needle pricks are placed close to each other. Most authors consider that skin needling induces normal wound healing, developing in three phases.<sup>5</sup> Phase 1, the inflammation phase, starts soon after the injury; platelets release chemotactic factors, which cause invasion of other platelets, neutrophils and fibroblasts. During proliferation (phase 2), neutrophils are replaced by monocytes that change into

macrophages and release several growth factors including platelet-derived growth factor, fibroblast growth factor, and transforming growth factors  $\alpha$  and  $\beta$ , which stimulate the migration and proliferation of fibroblasts. Keratinocytes then become mobile to cover the gap in the basement membrane. They start producing all the components to re-establish the basement membrane with laminin and collagen types IV and VII. A day or two after PCI, the keratinocytes begin to proliferate and release growth factors to promote collagen deposition by the fibroblasts. Tissue remodeling (phase 3) continues for months after the injury and is mainly achieved by the fibroblasts: collagen type III is laid down in the upper dermis and is gradually replaced by collagen type I over a period of a year or longer. Matrix metalloproteinases (1–3) are essential for the conversion process.<sup>5</sup>

Recently, a new hypothesis has been proposed to explain the PCI mechanism of action:<sup>6</sup> when CIT is performed using a high-quality device, the fine microneedles do not create a wound in the classic sense. The wound healing process is cut short, as the body is somehow 'fooled' into believing that an injury has occurred. According to this new theory, bioelectricity (also called 'demarcation current') triggers a cascade of growth factors that stimulate the healing phase. When microneedles penetrate the skin, they cause fine wounds. Cells react to this intrusion with a demarcation current that is additionally increased by the needles' own electrical potential. In some findings by Jaffe *et al.*,<sup>7</sup> the membrane of a living cell has been shown to have a resting electrical potential of  $-70$  mV. The electrical potential depends greatly on the transport mechanisms. If a single acupuncture needle comes close to a cell, the inner electrical potential quickly increases to  $\geq -100$  mV. Cell membranes react to the local change with an electrical potential that creates increased cell activity and release of potassium ions, proteins and growth factors.

Although the mechanism of action is still unclear, the final result is deposition of new collagen in the upper dermis.

Patients	1	2	3	4	5	6	7	8	9	10	11	12	13	14	15	16	17	18	19	20	21	22	23	24	25	26	27	28	29	30	31	32
Sign of differences between the scores	0	-	0	-	-	-	-	0	0	-	0	-	0	-	-	0	0	0	-	0	0	-	0	-	0	0	0	-	-	0	-	0

Figure 3 The sign test for non-parametric data.

There is no simple and definitive solution for acne scarring, which is a difficult problem to treat. A combination of several treatment procedures may be appropriate, depending on specific patient features. The results of this study, however, confirm that CIT is a simple technique and can have an immediate effect on the improvement of rolling acne scars. In accordance with the literature, the full result may take 8–12 months of treatment to occur, as the deposition of new collagen takes place slowly. As shown by Fernandes and Signorini,<sup>8</sup> CIT has undisputable advantages compared with conventional methods. The most important is that the epidermis remains intact because it is not damaged, eliminating most of the risks and negative side-effects of chemical peeling or laser resurfacing. Histological examination showed that the skin was indistinguishable from normal skin and that the epidermis showed more dermal papillae. Skin became thicker, with greatly increased collagen deposition and significantly more elastin. Recently, Aust *et al.* showed a considerable increase in collagen and elastin deposition at 6 months postoperatively. The epidermis showed 40% thickening of the stratum spinosum and normal rete ridges at 1 year postoperatively.<sup>9</sup>

Skin needling and all its therapeutic possibilities are now being researched intensively. There is scientific proof that the needling procedure also stimulates revascularization, repigmentation of stretch marks and filling of cutaneous wrinkles. We believe that skin needling is a simple and rapid method for safe treatment of acne scars and a suitable procedure for various dermatological conditions.

## Acknowledgements

We would like to thank the staff of DermIng S.r.l., who contributed to this study.

## References

- 1 Jacob CI, Dover JS, Kamminer MS. Acne scarring. A classification system and review of treatment options. *J Am Acad Dermatol* 2001; **45**: 109–17.
- 2 Orentreich DS, Orentreich N. Subcutaneous incisionless (subcision) surgery for the correction of depressed scars and wrinkles. *Dermatol Surg* 1995; **21**: 543–9.
- 3 Fernandes D. Minimally invasive percutaneous collagen induction. *Oral Maxillofac Surg Clin North Am* 2005; **17**: 51–63.
- 4 Camirand A, Doucet J. Needle dermabrasion. *Aesthetic Plast Surg* 1997; **21**: 48–51.
- 5 Cohen KI, Diegelmann RF, Lindbland WJ. *Wound Healing. Biochemical and Clinical Aspects*. Philadelphia, WB Saunders Co; 1992.
- 6 Liebl H. Abstract reflections about collagen-induction-therapy (CIT). A hypothesis for the mechanism of action of collagen induction therapy (CIT) using micro-needles. <http://www.dermaroller.de/us/science/abstract-reflections-26.html> (accessed 30 October 2008).
- 7 Jaffe L. Control of development by steady ionic currents. *Fed Proc* 1981; **40**: 125–7.
- 8 Fernandes D, Signorini M. Combating photoaging with percutaneous collagen induction. *Clin Dermatol* 2008; **26**: 192–9.
- 9 Aust MC, Fernandes D, Kolokythas P *et al.* Percutaneous collagen induction therapy. An alternative treatment for scars, wrinkles, and skin laxity. *Plast Reconstr Surg*, 2008; **121**: 1421–9.